

First-In-Human Study with a Novel Synthetic Bone Graft, OssDsign Catalyst™, in Transforaminal Lumbar Interbody Fusion with Instrumented Posterolateral Fusion

A Lazary¹, PP Varga¹, L Kiss¹, Z Szoverfi¹, S Czop² and R Archer^{3*}

¹Budai Egeszsegkozpont Zrt, Investigators for study, Hungary

²OssDsign A, B, United States of America

³Archer Clinical Ltd, Consultant to OssDsign A.B, United Kingdom

***Corresponding author:** Rosalyn Archer, Archer Clinical Ltd, consultant to OssDsign A.B, United Kingdom

ARTICLE INFO

Received: 📅 January 10, 2024

Published: 📅 January 24, 2024

Citation: A Lazary, PP Varga, L Kiss, Z Szoverfi, S Czop and R Archer. First-In-Human Study with a Novel Synthetic Bone Graft, OssDsign Catalyst™, in Transforaminal Lumbar Interbody Fusion with Instrumented Posterolateral Fusion. Biomed J Sci & Tech Res 54(4)-2024. BJSTR. MS.ID.008571.

ABSTRACT

Study Design: First-in-human use of a novel bone graft in spine surgery: an open-label, prospective, single-centre clinical study.

Background: The use of synthetic bone graft substitutes has become more common to avoid the need to source allograft or iliac crest autograft. A new nanosynthetic, silicate-enriched calcium phosphate bone graft substitute, OssDsign Catalyst™ (formerly Osteo3 ZP Putty), has been designed to deliver consistent and rapid bone healing and remodeling. The high level of substituted silicate (5.8 wt%) in the porous granules combined with the nanoscale architecture is thought to promote early bone formation.

Objective: Intended to demonstrate the safety and performance of Catalyst synthetic bone graft in instrumented Transforaminal Lumbar Interbody Fusion.

Method: Seventeen adults aged 40-62 years old requiring TLIF surgery at one spinal level were included. Post-operative follow-up at 6 weeks, 3 months, 6 months, 12 months and 24 months. This paper reports the results up to 12 months follow-up. CT scans were taken at 3, 6, and 12 months post-operatively to assess the presence of fusion. CTs were independently radiologically reviewed by Medical Metrics Inc.

Standardized patient-reported outcome measures were collected at each timepoint (i.e., ODI, VAS, SF-36, GTO/PS) along with adverse events (AE).

Results: Of the 17 subjects recruited, three were withdrawn for reasons unrelated to Catalyst, the remaining 14 completed to 12-month follow-up. 4/14 (29%) subjects were fused at 3 months, 9/14 (64%) at 6 months, and 13/14 (93%) were fused at 12 months post-operative follow-up. ODI and VAS scores showed improvement in quality of life and pain respectively, at all post-operative follow-up evaluations.

No device-related AEs were observed.

Conclusions: This prospective series indicated OssDsign Catalyst™ bone graft substitute, demonstrates consistent and rapid bone healing and remodeling, with corresponding improved patient outcomes.

Keywords: Synthetic Bone Graft; Nanosynthetic; Silicate Enriched Calcium Phosphate; TLIF, Spine Fusion

Introduction

Degenerative disc disease and spinal stenosis are two of the major spine pathologies resulting in low back and leg pain as well as functional limitations that are prevalent today [1]. When symptoms are not responsive to conservative care, surgery may be recommended. Spinal fusion was introduced for the management of deformity and has for the past several decades been used to relieve pain and restore function in subjects diagnosed with degenerative disc disease. The objective of spinal fusion is to eliminate motion of the vertebral body and decompress spinal nerves thereby relieving pain [2]. Spinal fusion is a common procedure requiring hardware and a source of bone grafting material. Common bone graft materials include autograft (patient's own bone), allograft (donor bone), or a bone graft substitute [3] which may be synthetic or from an alternative biological source [4]. The most common source of autograft is local bone removed from the spinal region during the surgical procedure and morselized. This is often limited in quantity and can vary in bone quality. Allograft (donor bone) can be in short supply and there is no assurance of freedom from disease. Depending on the processing method, it can be highly variable in performance. As a result of these limitations, there is increased interest in synthetic bone graft substitutes [5].

OssDsign Catalyst™ (formerly Osteo [3] ZP Putty), hereon referred to as Catalyst, is a new nanosynthetic calcium phosphate bone graft substitute, containing the highest level of substituted silicate ions (5.8 wt%) in any bone graft. It is osteoconductive, resorbable, porous and 100% synthetic without the need for adding any biological materials. Catalyst contains silicate enhanced calcium phosphate granules suspended in a resorbable gel carrier, which enables direct implantation from the packaging without any further processing time. The physical and chemical properties of Catalyst combined with a high surface area of the porous granules have been designed to deliver consistent and rapid bone ingrowth, remodeling and cell-mediated resorption during the bone healing process, as shown in clinically relevant animal studies [6,7]. These studies showed that Catalyst achieves fusion success rates comparable to iliac crest bone graft (ICBG), the traditional 'gold standard' [8]. This is a first-in-human, open-label, prospective, single-centre clinical study intended to demonstrate the safety and performance of Catalyst synthetic bone graft in Transforaminal Lumbar Interbody Fusion (TLIF) procedures with instrumented posterolateral fusion (PLF). The TLIF approach was chosen for this clinical study as it is now a popular surgical approach as it is minimally invasive and avoids significant retraction of the dura and nerve roots.

By removing one of the facet joints, a different trajectory is adopted to take out the disc and insert bone graft and a cage into the disc space. This exposes the nerves to a lower risk of injury and requires less muscle retraction, thus reducing the risk of post-operative and long-term back pain [9]. The aim of this prospective, single centre first-in-human study is to demonstrate safety of this novel synthetic bone graft by review of any device related serious adverse events

(SAEs) to 24 months post-operative follow-up as well as performance assessed by fusion rates at 3, 6, 12 and 24 months post-operative follow-up. This paper will describe the study findings to 12 months follow-up.

Materials and Methods

Seventeen subjects were recruited and underwent one level TLIF procedures (L2-S1) with instrumentation and Catalyst nanosynthetic bone graft. To address the theoretical risk of migration into the spinal canal, the bone graft was mixed in a 1:1 ratio with morselized autologous bone taken from the facetectomy for placement posterior to the interbody cage; elsewhere the bone graft was used without mixing (i.e., anterior to and within the interbody cage and in the posterolateral gutter contralateral to the side of the laminectomy or bi-laterally if large transverse processes are present). Inclusion criteria included adults (40-65 years old) with degenerative disc disease (DDD), degenerative spondylolisthesis or lumbar spinal stenosis requiring surgery at one spinal level; the subjects had failed to gain adequate relief after at least six months of non-operative treatment prior to clinical study enrolment (e.g., bed rest, physical therapy, bracing, traction, drug therapy). Subjects were excluded from the study if they required a fusion procedure over more than one level or had had prior surgery at the index surgical level, had a systemic or surgical site infection, a history of significant metabolic bone disease, or other diseases that would place the patient at excessive risk to surgery, history of substance abuse, known to be pregnant and/or breastfeeding, Body Mass Index (BMI) ≥ 40 , participating in another clinical trial, or a medical condition that could interfere with the bone healing process or their attendance at follow-up visits. All subjects provided their written informed consent before study data collection commenced.

The data presented compares the baseline data collected before surgery with data collected post-operatively at 6 weeks, 3 months, 6 months and 12 months. CT scans were taken at 3, 6, and 12 months post-operatively and were used to assess the presence of fusion. Successful fusion was defined as evidence of bridging bone (contiguous bony connection from the superior vertebral body to the inferior vertebral body, in the posterolateral gutter, in front of (anterior) or within the interbody cage. All CT scans were reviewed blinded by two independent (Medical Metrics Inc.) experienced radiologists, plus a third where the initial two disagreed. At each follow-up visit standardized Patient-reported Outcome Measures (PROMs) were completed including Oswestry Disability Index (ODI) [10,11] and back and/or radicular leg pain visual analog numerical scores (VAS), and SF-36 [12] quality of life questionnaires, plus Global Treatment Outcome (GTO) [13,14] and Patient Satisfaction (PS) questionnaires were collected at each timepoint. Safety was assessed by review of the type and prevalence of Catalyst related adverse events. All PROMs data was averaged and entered into Graph Pad software. This was used to compare the mean results to the baseline pre-operative data and where appropriate ordinary one-way ANOVA using multiple comparisons were per-

formed using Dunnett's multiple comparison test. This clinical study was conducted in accordance with the clinical study protocol, the principles of Good Clinical Practice (ICH-GCP) and in accordance with the Declaration of Helsinki, ISO 14155, FDA (21CFR) and the appropriate local regulations.

The study was completed at the Országos Gerincgyógyászati Központban (Buda Health Centre, Hungary) after receiving required local approvals by the Országos Gyógyszerészeti és Élelmezés-egészségügyi Intézet (OGYÉI) and the hospital ethics committee.

Results

Patient Demographics

Of the 17 subjects recruited to this study 14 reached post-operative 12 month follow-up. Three subjects were withdrawn from the study and not included in the analyses reported in this paper. One was diagnosed with cancer and had to withdraw; two were withdrawn after revision surgery to reposition mis-aligned instrumentation, during which the bone graft was removed. As can be seen in Table 1 below, 13 of the 14 subjects in this cohort were female, with a median age of 48 years, BMI of 29.7, one of whom was a smoker. Eleven of the subjects were diagnosed with degenerative disc disease (DDD) and/or degenerative spondylolisthesis (DS), with one having DS and spinal stenosis, and one having all three. Co-morbidities for which medication was being taken included: 1 patient with pulmonary disease, 2 with thyroid problems, 5 with hypertension, and 2 with thrombotic/embolic disorders, none of which were thought to have affected the subjects' bone fusion. The affected spinal level which underwent TLIF surgery was L4-L5 among 6 subjects and L5-S1 in the remaining 8 subjects. The surgery sites in all cases were stabilized with a PEEK interbody cage plus two titanium rods and four pedicle screws across the posterolateral transverse processes.

Table 1: Demographics.

Age: mean \pm SD (Range)	49 \pm 6 years (40 - 62 years)
Median (IQR)	48 (46 - 52 years)
Gender	13 Females; 1 Male
BMI (mean \pm SD) (Range)	30.0 \pm 4.4 (22.4 - 39.0)
Median (IQR)	29.7 (27.2 - 33.0)

Vertebral levels: n	L4-L5: 6; L5-S1: 8
Primary diagnosis:	
Degenerative spondylolisthesis	11
Degenerative disc disease	11
Stenosis	2
Co-morbidities:	
Hypertension	5
Thyroid	2
Pulmonary Disease	1
Thrombosis/Embolic Disease	1
Smoker	1 (20 cigarettes/day)

Radiographic Outcomes

Fusion results assessed by CT scans at the 3, 6 and 12-month follow-ups are shown in Table 2. Early fusion was seen in 4/14 (29%) of subjects at 3 months. At 6 months follow-up 9/14 (64%) subjects were fused and at the 12 months post-operative follow-up 13/14 (93%) were fused. An example is shown in Figure 1.

Table 2: Rates of Successful Fusion (%).

Follow-up evaluation	Overall Fusion Rate
3 months:	
Fused	4/14 (29%)
Partial*	10/14 (71%)
None	0/14 (0%)
6 months:	
Fused	9/14 (64%)
Partial*	5/14 (36%)
None	0/14 (0%)
12 months	
Fused	13/14 (93%)
Partial*	1/14 (7%)
None	0/14 (0%)

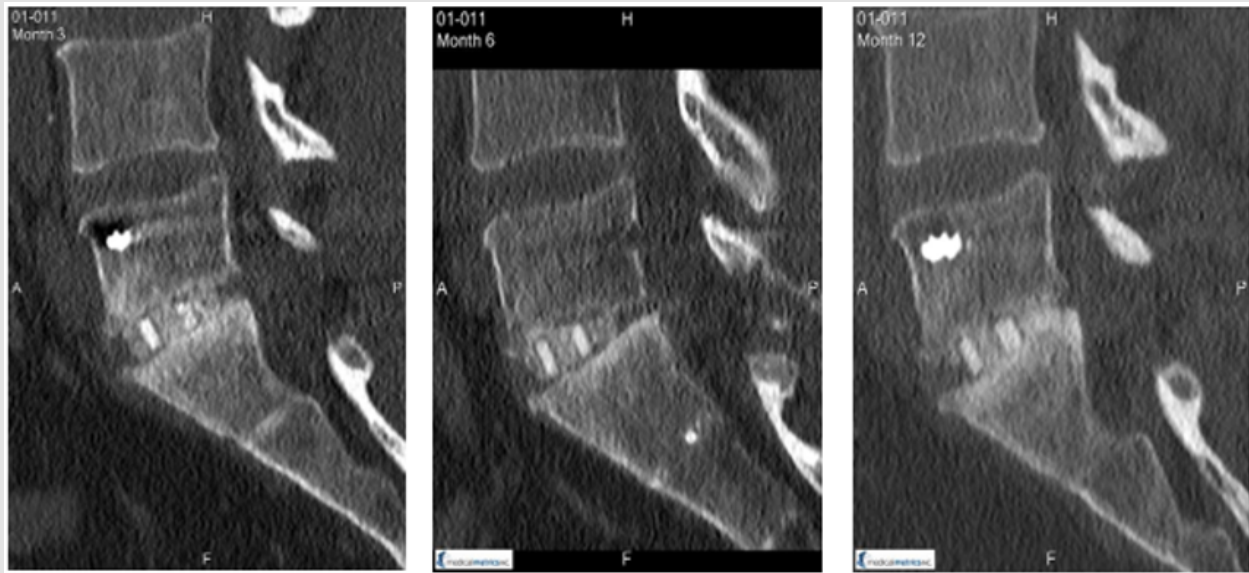


Figure 1: Subject #011 Fusion images at 3, 6 and 12 month follow-up.

Clinical Outcomes

Both the mean VAS (Figure 2) and ODI (Figure 3) showed a decrease in pain and improvement in quality of life at all follow-up visits compared to the baseline pre-operative scores. All follow-up evaluations showed significant improvement from pre-operative baseline Quality of Life data in all categories (Figure 4). The subjects overall assessment of their health transition (Figure 5) also showed a sig-

nificant improvement at each follow-up evaluation with all post-operative scores being between one and two (i.e., their health being much better, or somewhat better, than one year ago). This result was reflected in the Global Treatment Outcome score (GTO) and patient satisfaction scores (PS). Mean scores showed all subjects saying that the surgery helped or helped a lot (GTO of 4.8/5) and that they were very satisfied (PS of 4.9/5).

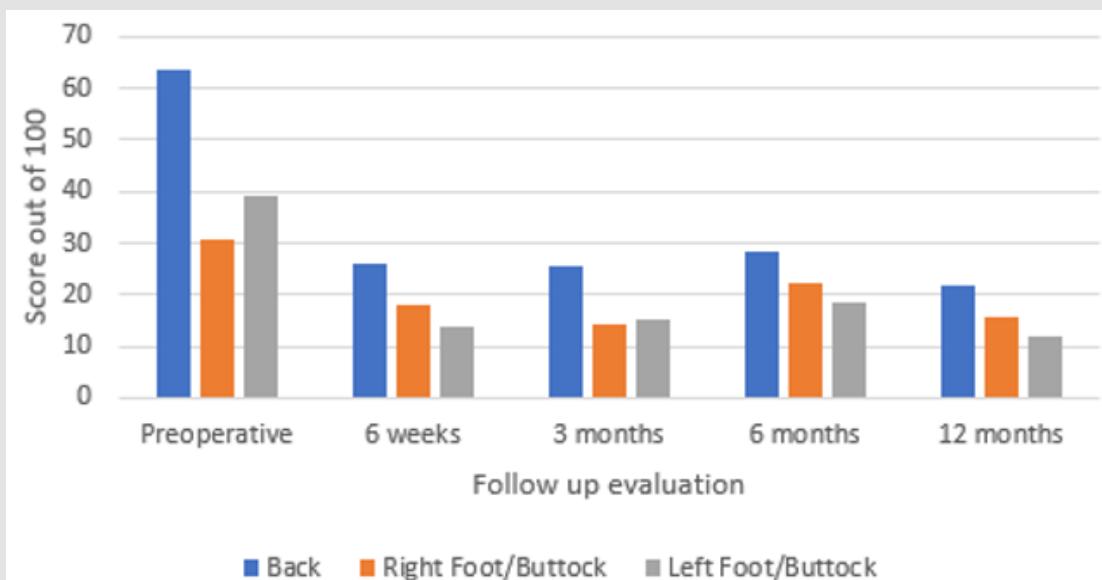


Figure 2: Mean Visual Analogue Scores for Pain.

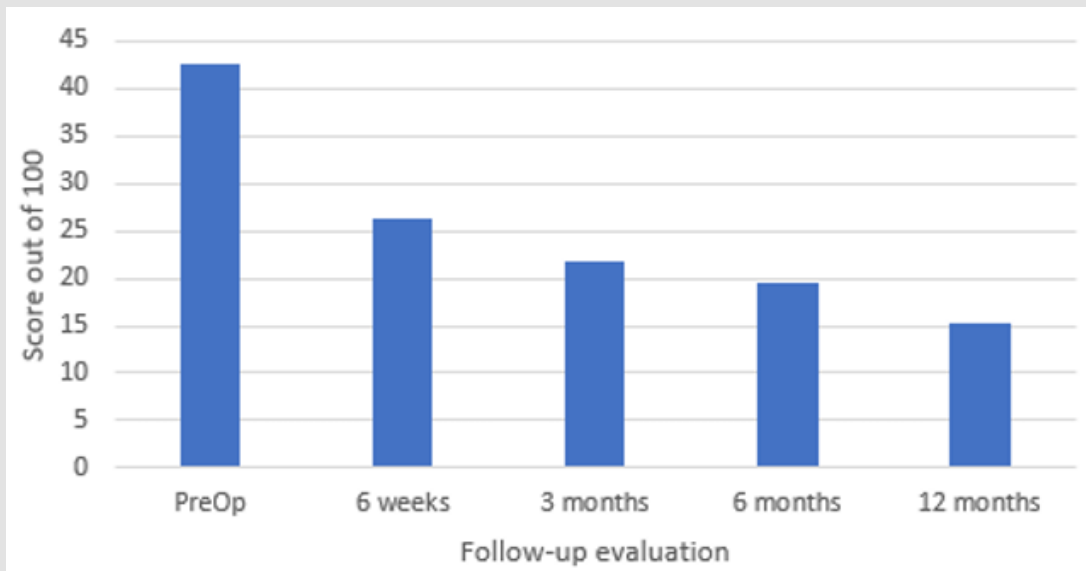


Figure 3: Mean Oswestry Disability Index Scores.

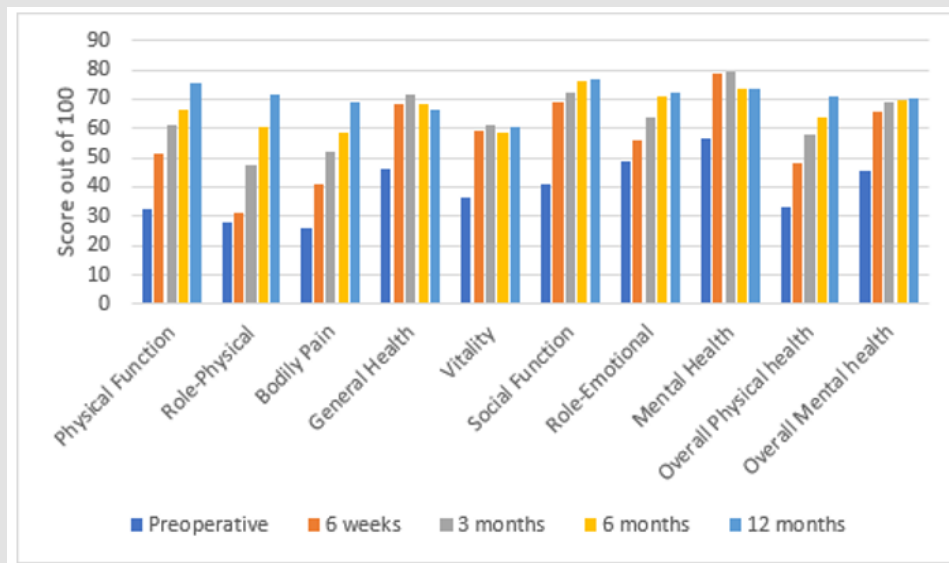


Figure 4: Mean SF-36 Quality of Life scores.

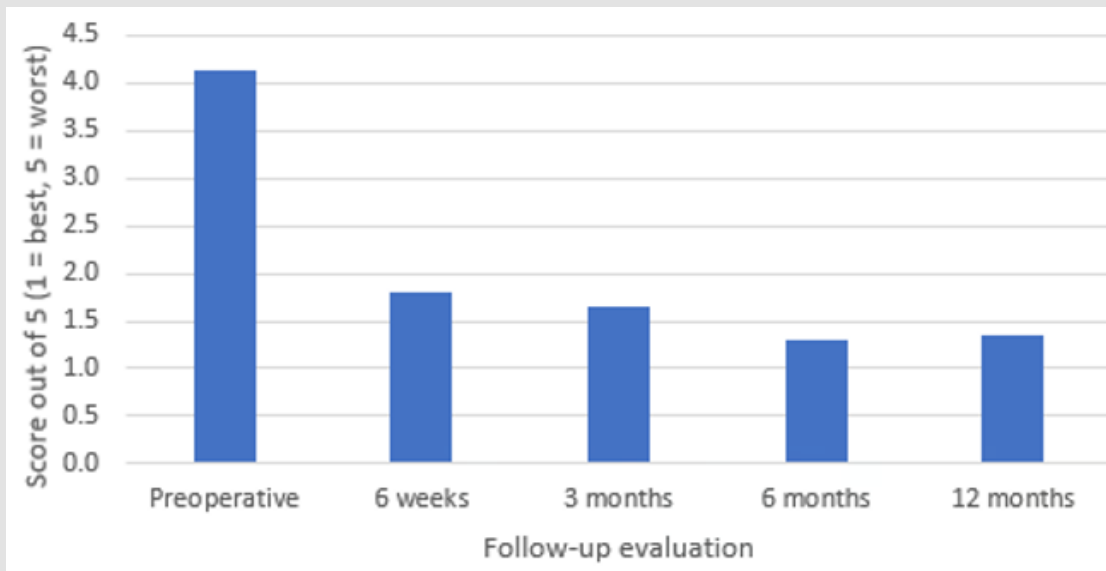


Figure 5: Mean SF-36 - Health Transition Scores.

Adverse Events

There were no adverse events related to the Catalyst bone graft. There were twelve (12) adverse events recorded among the 17 subjects originally recruited to this study (Table 3). Three were withdrawn from the study and did not attend the 3-month post-operative follow-up evaluations or any thereafter. One was diagnosed with a pancreas head tumor, was unable to attend follow-up evaluations and unfortunately died and two had revision surgery in which the bone graft was removed. Two subjects required revision surgery in which

the bone graft was removed, so were withdrawn from the study. One had revision surgery and debridement at L5/S1 level due to a misplaced pedicle screw and wound infection. The graft material and intervertebral PEEK spacer were removed to avoid chronic infection. The other subject required revision surgery due to fracture of the L5 pedicles, due to the sub-optimal placement of a pedicle screw, instability of the L4-5 segments, and bilateral L5 nerve root compression in which the bone graft was disturbed and removed from the posterolateral gutter.

Table 3: Adverse Events.

Adverse Event Description	N (%) of Subjects out of the 17 recruited	Related to procedure	Related to Catalyst
Gallstones	1 (6%)	No	No
Pancreatic head tumour	1 (6%)	No	No
Stroke	1 (6%)	No	No
Lower back pain after a fall	1 (6%)	No	No
Seroma	1 (6%)	Yes	No
Radiculitis	1 (6%)	Yes	No
Sub-optimal pedicle screw placement (revision surgery performed)	2 (12%)	Yes	No
Mechanical failure, L5 pedicle fracture (revision surgery performed)	1 (6%)	Yes	No
Wound infection	3 (18%)	Yes	No

Discussion

Results from the first 14 subjects to receive Catalyst synthetic bone graft in this single centre prospective study are encouraging with early fusion evident in 9/14 (64%) of subjects at 6 months and 13/14 (93%) of subjects at 12 months post-operative follow-up 6 below. The remaining patient has evidence of fusion progression so may be fused at the 24-month follow-up visit. literature review of TLIF surgeries and outcomes from 2010 to the present indicates fusion success rates at 12 months to range from 77% to 100% [8,15-21]. The early fusion results in this series (64% at 6 months via CT) compare favorably to the results obtained by vonderHoeh et al. [8]. In a prospective study using ICBG or local bone mixed 1:1 with hydroxyapatite bone graft, fusion rates of 62.5% for the ICBG group at 6 months post-surgery; 58% fusion for the mixed group using standard x-rays were reported. At 12 months post-operation fusion rates of 83% for both groups were reported using CT scans [8]. Clinical results which included VAS, ODI, and SF-36 showed significant symptom relief at each timepoint up to the 12-month follow-up and there were no bone graft-related adverse events.

Limitations of the Study

In this first-in-human study the number of subjects was small, and the study was conducted at a single centre. Catalyst performed well but it is recognized that further larger multi-centre investigations are required.

Conclusion

This prospective series indicated OssDsign Catalyst™, a new nano-synthetic calcium phosphate bone graft substitute, demonstrates consistent and rapid bone healing and remodeling, with corresponding improved patient outcomes.

Acknowledgments

The authors would like to thank the site study co-ordinators, Julia Szita and Edit Pap for all their hard work on this study.

References

- Katz JN (1995) Lumbar spinal fusion. Surgical rates, costs, and complications. *Spine (Phila Pa 1976)* 20: 78S-83S.
- Weiner BK, Fraser RD (1998) Lumbar Interbody Cages. *Spine (Phila Pa 1976)* 23: 634-640.
- Brandoff JF, Silber JS, Vaccaro AR (2008) Contemporary alternatives to synthetic bone grafts for spine surgery. *Am J Orthop (Belle Mead NJ)* 37: 410-414.
- Vaccaro AR, Kazuhiro C, Heller JG, Patel TC, Thalgott JS, et al. (2002) Bone grafting alternatives in spinal surgery. *The Spine Journal* 2.
- Ehrler DM, Vaccaro AR (2000) The Use of Allograft Bone in Lumbar Spine Surgery. *Clin Orthop Relat Res* 371: 38-45.
- Sirakoss (Unpublished) (2018) Osteo3 ZP Putty Preclinical Results From 510(k), internal report.
- Conway JC, Oliver RA, Wang T, Wills DJ, Herbert J, et al. (2021) The efficacy of a nanosynthetic bone graft substitute as a bone graft extender in rabbit posterolateral fusion. *The Spine Journal* 21: 1925-1937.
- VonderHoeh NH, Voelker A, Heyde CE (2017) Results of lumbar spondylo-deses using different bone grafting materials after transforaminal lumbar interbody fusion (TLIF). *Eur Spine J* 26(11): 2835-2842.
- (2020) Precision brain, spine and pain centre (2020). Transforaminal lumbar interbody fusion (TLIF).
- Fairbank JCT, Pynsent PB (2000) The Oswestry Disability Index. *Spine (Phila Pa 1976)* 25: 2940-2953.
- Little DG, MacDonald D (1994) The use of the percentage change in Oswestry Disability Index score as an outcome measure in lumbar spinal surgery. *Spine (Phila Pa 1976)* 19(19): 2139-2143.
- Ware JE, Kosinski M, Dewey JE (2001) How to score Version 2 of the SF-36 Health Survey. Lincoln, RI: Quality Metric Incorporated.
- Mannion AF, Porchet F, Kleinstuck FS, Lattig F, Jeszenszky D, et al. (2009) The quality of spine surgery from the patient's perspective: Part 1. The Core Outcome Measures Index in Clinical Practice. *Eur Spine J* 18(3): 367-373.
- Mannion AF, Porchet F, Kleinstuck FS, Lattig F, Jeszenszky D, et al. (2009) The quality of spine surgery from the patient's perspective: Part 2. Minimal clinically important difference for improvement and deterioration as measured with the Core Outcome Measures Index. *Eur Spine J* 18(3): 374-379.
- Yoo JS, Min SH, Yoon SH (2015) Fusion rate according to mixture ratio and volumes of bone graft in minimally invasive transforaminal lumbar interbody fusion: minimum 2-year follow-up. *Eur J Orthop Surg Traumatol* 25 Suppl 1: S183-9.
- Challier V, Boissiere L, Obeid I, Vital JM, Jean-Etienne Castelain JE, et al. (2017) One-Level Lumbar Degenerative Spondylolisthesis and Posterior Approach: Is Transforaminal Lateral Interbody Fusion Mandatory?: A Randomized Controlled Trial With 2-Year Follow-Up. *Spine (Phila Pa 1976)* 42(8): 531-539.
- Wu WJ, Li Y, Hou TY, Cheng P, Zhang ZH, et al. (2019) Application of New Allogeneic Lumbar Fusion Cage (Biocage) in Single-Segment Lumbar Degenerative Disease: A Prospective Controlled Study with Follow-Up for ≥2 Years. *World Neurosurg* 126: e1309-e1314.
- Rapan S, Jovanović S, Gulan G (2010) Transforaminal lumbar interbody fusion (TLIF) and unilateral transpedicular fixation. *Coll Antropol* 34(2): 531-534.
- Mura PP, Costaglioli M, Piredda M, Caboni S, Casula S (2011) TLIF for symptomatic disc degeneration: a retrospective study of 100 subjects. *Eur Spine J* 20 Suppl 1(Suppl 1): S57-60.
- Poh SY, Yue WM, Chen LTJ, Guo CM, Yeo W, et al. (2011) Two-year outcomes of transforaminal lumbar interbody fusion. *J Orthop Surg (Hong Kong)* 19(2): 135-140.
- Wang HW, Hu YC, Wu ZY, Wu HR, Wu CF, et al. (2017) Minimally Invasive Transforaminal Lumbar Interbody Fusion and Unilateral Fixation for Degenerative Lumbar Disease. *Orthop Surg* 9(3): 277-283.

ISSN: 2574-1241

DOI: 10.26717/BJSTR.2024.54.008571

Rosalyn Archer. Biomed J Sci & Tech Res



This work is licensed under Creative Commons Attribution 4.0 License

Submission Link: <https://biomedres.us/submit-manuscript.php>



Assets of Publishing with us

- Global archiving of articles
- Immediate, unrestricted online access
- Rigorous Peer Review Process
- Authors Retain Copyrights
- Unique DOI for all articles

<https://biomedres.us/>